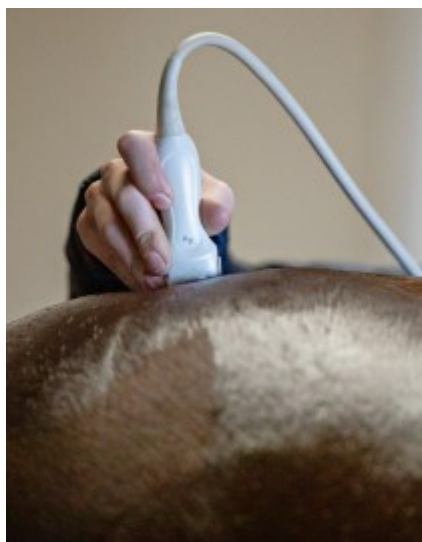
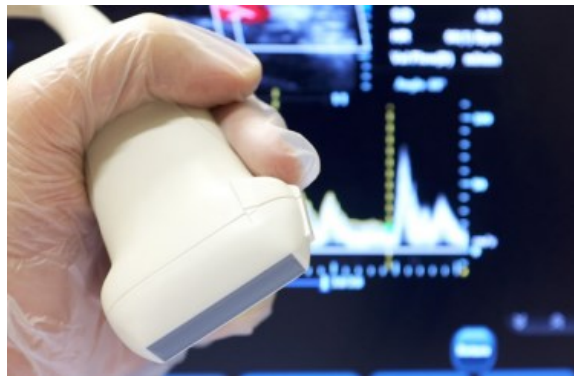



Ultrasonography

What is Ultrasonography?

Ultrasonography is a valuable and widely used diagnostic tool in horses, which diagnose and evaluate a number of conditions. An ultrasound captures live images from inside the horse's body and unlike some other imaging techniques, it does not use radiation.



How does it work?

Ultrasound uses high-frequency sound waves that pass through the body before reflecting and bouncing back to the handpiece. This echo is transformed into a picture by the computer. Different tissues reflect the ultrasound in different ways and this allows us to visualise structures in great detail. Additionally, colour doppler ultrasound uses the way ultrasound reflects differently in moving blood to show how it is flowing.

Advantages of ultrasonography

- Non-invasive process
- Painless Ultrasound images are real-time, so you are able to see direct visualisation
- Ultrasonography does not use radiation
- Doppler ultrasound can measure the speed of blood flow
- Ultrasound captures images of soft tissue that don't show up on an x-ray
- The equipment is mobile
- Ultrasounds are usually quick, with most sessions lasting around 20-30 minutes





Kings Bounty Equine Practice Client Fact Sheet

What can be seen?

Musculoskeletal system

Ultrasonography is used extensively in lameness investigations for the scanning of tendon and ligament injuries as well as assessing wounds, joint surfaces, fractures and soft tissue swellings. Ultrasonography may also be useful for the detection of back and pelvic injuries.

Heart and vascular system

Ultrasonography of the heart is important to assess the chambers and valves of the heart and is invaluable in the assessment of the significance of many types of heart murmur. Colour flow Doppler is used to assess dynamic blood flow through different parts of the heart. Ultrasonography may also be useful for assessing thrombi and peripheral blood vessels.

Abdomen

Ultrasonographic examination of the intestines and other abdominal structures (eg. liver, kidneys and spleen) is an important diagnostic tool in the investigation of horses with colic, weight loss or diarrhoea. Ultrasound guidance is frequently used to allow safe and precise biopsy of internal structures such as the liver, lungs and kidneys.

Reproductive Tract

Ultrasonographic assessment of the ovaries and uterus is important in the management of brood mares to assess the reproductive tract, stage of oestrous cycle and pregnancy diagnosis. Regular ultrasound scans of the ovaries are performed (every few hours) of mares undergoing artificial insemination (AI) to ensure that insemination is performed at the optimal time. Early pregnancy diagnosis is important to ensure that a mare is not carrying twins.

Thorax

Ultrasonographic assessment of the thoracic cavity, including the lungs, is important in the assessment of horses with pneumonia, lung masses or pleurisy.

